

WHAT ELSE MAY LOOK LIKE A STY?

1 Chalazion

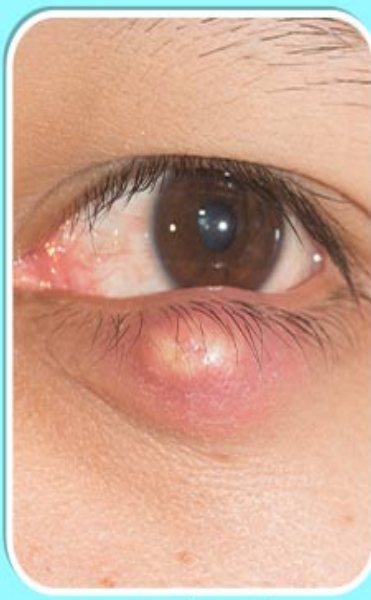


Image Source: Shutterstock

- Is an inflammation due to a blocked oil gland
- Lump in the upper or lower eyelid may resemble a sty

Differences from sty

- Not caused by infection
- Usually occur farther from an eyelid's edge
- Lump is harder
- Usually not painful

2 Sebaceous gland carcinoma

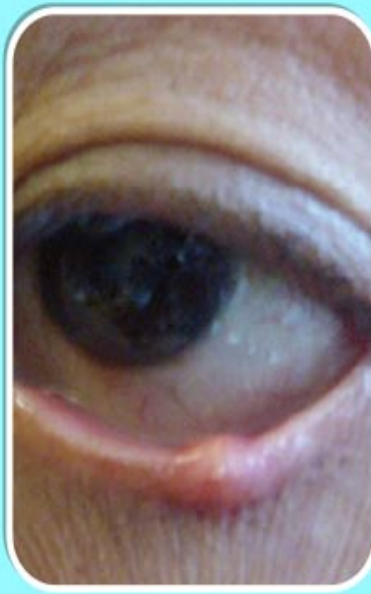


Image Source: British Journal of General Practice

- Yellowish, firm lump may initially look like a sty

Differences from sty

- Lump is painless
- May bleed
- Sore doesn't heal or frequently recurs

3 Preseptal cellulitis

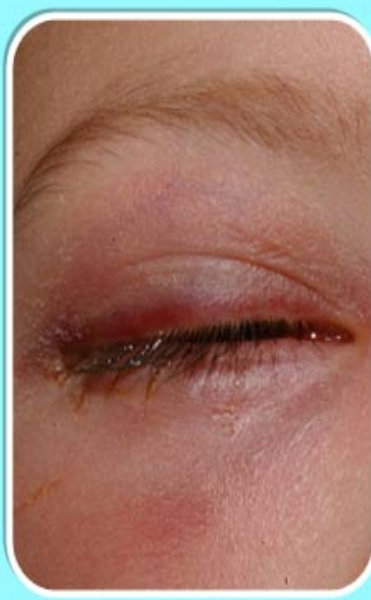

Image Source: The University of Utah

- Infection of the eyelid and the soft tissues surrounding the eye orbit
- May be caused by insect bites, trauma, or as an after-effect of a sty or chalazion
- Initial symptoms are redness and swelling of eyelids that may be mistaken for a sty

Differences from sty

- Inflammation more diffuse
- May take longer to resolve

References

- 1 Hordeolum; National Library of Medicine
- 2 Chalazion and Sty; University of Michigan Health
- 3 What Are Styes and Chalazia? American Academy of Ophthalmology
- 4 Skin Cancer Types: Sebaceous Carcinoma Signs & Symptoms; American Academy of Dermatology Association
- 5 Management of preseptal and orbital cellulitis; NCBI
- 6 Differential Diagnosis of the Swollen Red Eyelid; American Family Physician