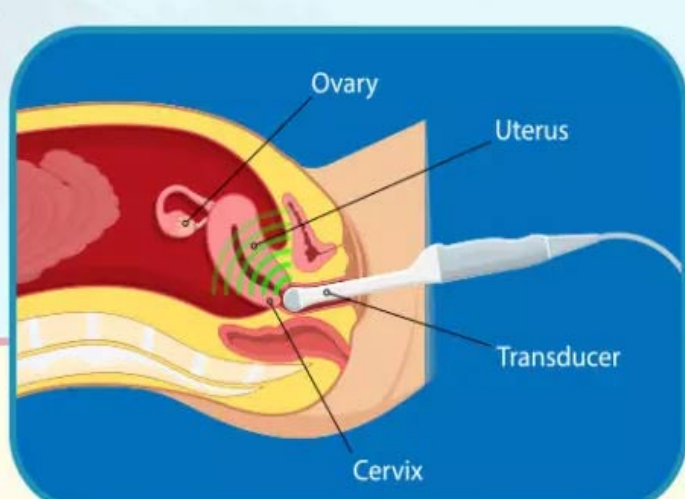


8th Week Scan:

Transvaginal Vs. Transabdominal

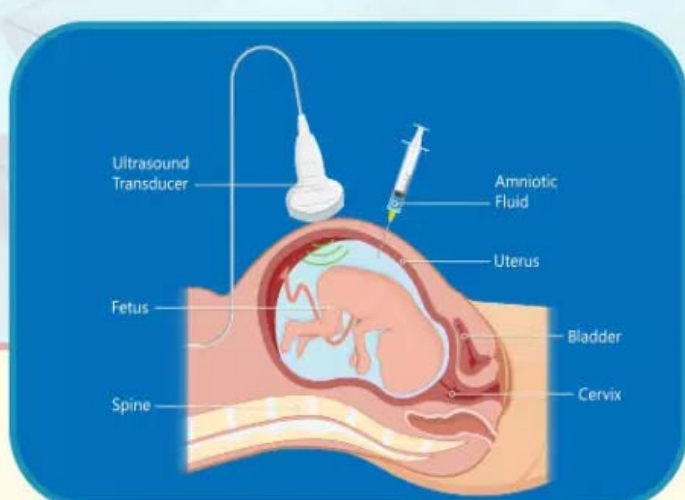


Transvaginal Ultrasound



- Imaging is done by placing a wand-like device in the vagina
- Can detect fetus and heartbeats from early weeks
- No need to apply pressure for a better image
- Empty bladder is needed before the procedure
- The transducer is covered with a plastic sheath or condom

Transabdominal Ultrasound



- Imaging is done by placing a transducer over the abdomen
- Clearer baby images are obtained after 12 weeks
- Slight pressure with a transducer on the abdomen provides a better image
- Often need to keep full bladder for better images
- The transducer can be placed without covering

Reference

1. Ultrasound In Pregnancy; Stanford Medicine